

### Comparative Characteristics of the Morphometric Parameters of the Kidney in Polypharmacy with Anti-Inflammatory Drugs

Mustafojev Zafarjon Mustafo oqli

Samarkand state medical university

#### Article Information

**Received:** December 09, 2022

**Accepted:** January 10, 2023

**Published:** February 11, 2023

**Keywords:** *anti-inflammatory drugs, kidneys, white rats, morphometric parameters*

#### ABSTRACT

At the global level, there has been an increase in the number of diseases caused by disorders of the urinary system. The studies were carried out on 250 five-month-old outbred white rats. This article studied changes in the morphometric parameters of the kidney under conditions of polypharmacy with 5 types of anti-inflammatory drugs. Polypharmacy of anti-inflammatory drugs had a negative effect on the morphometric parameters of the structural elements of the kidney. As a result of polypharmacy, the area of the renal corpuscle increased (up to 6.23%), the area of the cavity of the renal capsule (up to 12.36%), the area of the renal corpuscle (up to 7.04%), proximal (up to 8.27%) and distal caused a decrease the diameter of the convoluted tubules (up to 8.77%).

**Relevance.** Anti-inflammatory drugs are one of the most widely used drug groups in medicine. Their advantage is the complex effect, as well as the wide range of indications for which they can be used. As a result of many studies, among people who took anti-inflammatory drugs, the rate of death due to kidney pathologies is 9%. But how these drugs affect the urinary system is of great interest, because the kidney is responsible for protecting the entire body from toxins. Adverse effects on the kidney tissue under the influence of drugs can lead to the development of toxemia, a decrease in immunity and a violation of homeostasis.

Currently, the issue of widespread use of anti-inflammatory drugs for the purpose of mobilizing the body's natural defenses, forming physiological and immunobiological reactions for the prevention and treatment of all diseases remains relevant. Statistics show that polypharmacy of anti-inflammatory drugs is common and any specialist doctor can do it. This is especially true during the COVID-19 pandemic. In order to improve the simultaneous use of drugs in unreasonable combinations, it is still relevant to study kidney morphometric changes in the case of polypharmacy for the rational use of drugs (Kuzmenko Yu.Yu., 2009).

In the developed countries of the world, the death rate from side effects of drugs ranks 4-5 among the population deaths. The presented statistics show that polypharmacy of anti-inflammatory drugs is common and can be used by any specialist doctors (Avtandilov G.G., 2012).

The high sensitivity of the kidney to the influence of various factors, its ability to be the first in the body to react positively with adaptive changes in cell architecture and morphological regeneration has already been proven in the experiment (Tyaglova I.Yu., 2013).

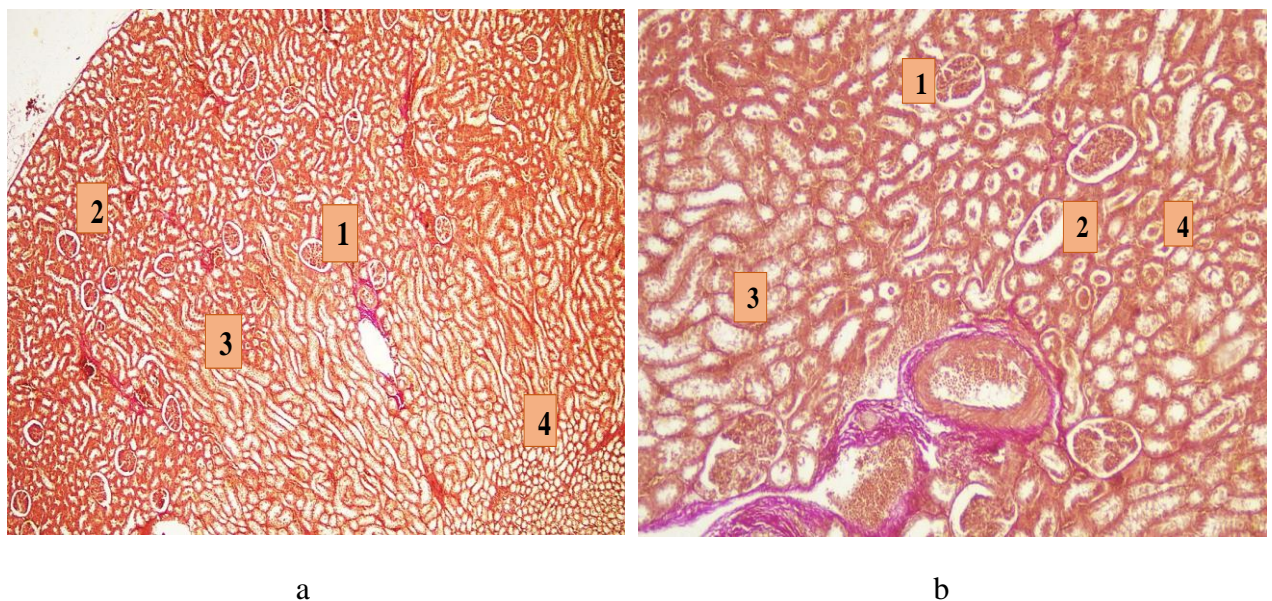
Reactive morphofunctional changes in the kidneys observed under the influence of damaging factors in the body allow determining the nature and intensity of the adaptive response of the kidney to this effect. Objective assessment of changes in the structural and functional state of the kidney paves the way for morphometric research methods that meet the modern requirements of evidence-based medicine [Volkov.V.P., 2015; Klyushin D.A., 2008].

During the study of the available literature, it was found that there is a lack of information about the morphometric changes of the kidney structure under the influence of polypharmacy.

**The purpose of the study** was to study the changes in the morphometric parameters of the kidney in the conditions of polypharmacy with 5 types of anti-inflammatory drugs.

**Material and methods.** Studies were conducted on 250 five-month-old purebred white rats. They were kept in normal vivarium conditions. 5 different anti-inflammatory drugs were used in polypharmacy. The following anti-inflammatory drugs were used to study the effects of polypharmacy in experimental groups of animals: Aspirin (AID - salicylic acid derivatives), Paracetamol (AID - anilide derivatives), Ibuprofen (AID - propionic acid derivatives), Dexamethasone (synthetic hydrocorticosteroid), Plaquinil sulfate (anti-inflammatory effective antimalarial). Rats receiving 5 types of anti-inflammatory drugs, paracetamol 15 mg/kg, aspirin 5 mg/kg, ibuprofen 6 mg/kg, dexamethasone 0.1 mg/kg, hydroxychloroquine sulfate 6.5 mg/kg (n = 50). Doses of this drug were calculated empirically and administered as an intragastric solution every day for 10 days.

From 141 days to 150 days, rats in the control group were injected with 0.5 ml of distilled water through the gastrointestinal tract for 10 days.



- |   |   |
|---|---|
| 1. The bundle of collagen fibers is shriveled.              | 1. The bundle of collagen fibers is shriveled.              |
| 2. Reduced density.   | 2. Increased density.                                       |
| 3. Interstitial tissue collagen fibers have a smaller loop. | 3. Interstitial tissue collagen fibers have a smaller loop. |
| 4. Intermediate fibers are sparse.                          | 4. Intermediate fibers are reduced.                         |

**Figure 5.** Kidneys of white rats exposed to 5 different AID drugs in the experiment. Stained by the Van Gieson method. (a) Ok 10 x Ok 10; (b) Ok 10 x Ok 20.

**Research results.** In the experiment, the absolute weight of the kidneys of rats was from 908,83 mg to 1074,36 mg, the average was  $987,93 \pm 3,06$  mg, the length of the kidney was from 12,09 mm to 13,28 mm, the average was  $12,73 \pm 0,63$  mm, width - from 6,04 mm to 7,64 mm, average –  $6,87 \pm 0,53$  mm, thickness from 4,84 mm to 5,76 mm, average –  $5,28 \pm 0,41$  mm, in this case, the volume of the kidney varied from 829,63 mm<sup>3</sup> to 1142,76 mm<sup>3</sup>, with an average of  $972,17 \pm 18,46$  mm<sup>3</sup>. The conducted histomorphometric studies showed that the total renal corpuscle area of experimental 5-month-old white rats ranged from 547,28 mkm<sup>2</sup> to 609,19 mkm<sup>2</sup>, the average was  $578,63 \pm 4,19$  mkm<sup>2</sup>, and the area of the vascular ball was from 326,41 mkm<sup>2</sup> to 407,16 mkm<sup>2</sup>, with an average of  $363,17 \pm 5,43$  mkm<sup>2</sup>, and the area of the capsule space ranged from 153,48 mm<sup>2</sup> to 274,28 mm<sup>2</sup>, with an average of  $224,19 \pm 3,54$  mm<sup>2</sup>.

**Conclusion.** Polypharmacy of anti-inflammatory drugs had a negative effect on the morphometric parameters of the structural structures of the kidney. Severe adverse reactions were observed when taking 5 types of anti-inflammatory drugs. As a result of polypharmacy, the area of the renal corpuscle (up to 6.23%), the area of the renal capsule cavity (up to 12.36%), the area of the renal corpuscle (up to 7.04%), proximal (up to 8.27%) and distal caused a decrease in diameter of tortuous tubules (up to 8.77%). Polypharmacy of anti-inflammatory drugs also has a negative effect on internal collagen fiber structures of the kidney, causing thinning of tufts due to thickening of collagen fibers, thinning of interstitial tissue, and shrinking of collagen fiber loops. As a result of polypharmacy, there were no significant changes in the diameters of the kidney blood vessels, but the fullness of the vessels and the area of the nephron vascular ball were observed.

## Literature

1. Mustafoyev Z.M., Teshayev Sh. J. Relativial Description of Kidney Morphometric Parameters in Polypharmacy of Anti-Inflammatory Pills. // American Journal of Medicine and Medical Sciences – 2022, – N12(8), – P. 862-867 (14.00.00.№ 2)
2. Mustafoyev Z.M., Baxronov J.J. Morphometric characteristics of parts of rat's kidney nephron in normality and in polypharmacia with anti-inflammatory preparation // Тиббиётда янги кун. -Бухоро – 2022, – №1 (39), – С. 276-278 (14.00.00.№22)
3. Мустафоев З.М, Бахронов Ж.Ж, Хидиров З.Э. Яллиғланишга қарши дори воситалари полипрагмазиясида буйрак нефронларида рўй берадиган морфометрик ўзгаришлар // Биология ва тиббиёт муаммолари. -Самарқанд –2022, –№ 3, – С. 177-181(14.00.19. № 136)
4. Мустафоев З.М, Тешаев Ш. Ж. Сравнительная характеристика морфологических параметров почек при полипрагмазии противовоспалительными препаратами // Биомедицина ва амалиёт журналы.-Самарқанд. – 2022, – № 1(7), – С. 69-73(14.00.00.№24)
5. Мустафоев З.М, Бахронов Ж.Ж Морфометрическая характеристика частей нефрона почек крыс в норме и при полипрагмазии противовоспалительными препаратами // Вестник ТМА – 2022, – №2, – С. 57-59 (14.00.00.№13)
6. Mustafoyev Z.M. Сравнительная характеристика морфологических показателей почек при полипрагмазии противовоспалительных препаратов // Тиббиётда янги кун.-Бухоро – 2022, – №9 (47), – С. 195-202 (14.00.00.№22)
7. Mustafoyev Z.M., Teshayev Sh. J., Bakhronov J. J.Features Of Kidneys Exposed to Various Factors // Eurasian Scientific Herald. –2022, –N 5, –P. 144-154 (Impact Factor 8.225)

8. Мустафоев З.М. Сравнительная характеристика морфологических параметров почек при полипрагмазии противовоспалительными препаратами // *Oriental Renaissance: Innovative, educational, natural and social sciences* – 2021, – N 1(8), – С. 622-630
9. Mustafoyev Z.M. Morphological Parameters Of Kidney In Polypragmasia With Anti Inflammatory Drugs // *The American Journal of Medical Sciences and Pharmaceutical Research*, – 2021, – N 3(10), – P. 33–37 .
10. Mustafoyev Z.M Comparative characteristics of morphometric parameters of kidneys in polypragmasia with anti-inflammatory drugs // *International Conference on Scientific Research and Advancements in Sciences Hosted from Hamburg, Germany* – 2021, – P. 137-138.
11. Мустафоев З.М. Сравнительная характеристика морфометрических параметров почек при полипрагмазии противовоспалительными препаратами // *Республиканской научно-практической конференции (с международным участием) молодых ученых. Актуальные вопросы патологической анатомии. Бухара* – 2021, – С. 51-52.
12. Mustafoyev Z.M . Hystopatology of kidney tissue in polypragmasia // *Innovation in the modern education system. (25<sup>th</sup> December,2021)-Washington, USA: "CESS",* – 2021, – №13, – P. 461-464
13. Тошмаматов Б.Н., Коржавов Ш.О., Усанов С.С., Мустафаев З.М. Polypragmasia as a risk factor causing complication in viral infection // *Central asian journal of medical and natural sciences Volume-02 Issue-02,* – 2021, – P. 79-82
14. Mustafoyev Z.M Analysis of polypragmasia prevalence and morphological changes of kidneys // *International Journal of Philosophical Studies and Social Science. Yangi O`zbekistonda milliy taraqqiyot va innovasiyalar. Республика илмий онлайн конференцияси. Тошкент,* – 2022, – P.105-108
15. Мустафоев З.М. Шарипова С.М. Строения почек и их изменение при полипрагмазии с противовоспалительными лекарственными средствами // “Ёш олимлар, магистр ва иктидорли талабаларнинг илмий фаолиятини оширишда уларга қаратилган креатив ғоялар, ечими ва таклифлар” Республика илмий конференцияси. –Тошкент, – 2022, – № 4, – 125-127-б.
16. Мустафоев З М., Вууракда polipragmaziya natijasida yuzaga keladigan morfologik o`zgarishlar bo`yicha electron dastur /Тошкент, 03.07.2022. № DGU15188.
17. Мустафоев З М., Тешаев Ш Ж. Яллиғланишга қарши дори воситалари полипрагмазиясида буйраклар морфометрик параметрларини аниқлаш методологияси // *Услубий тавсиянома.-Тошкент,* – 2022, 19 бет.
18. Aziza Zokirovna Olimova, (2021, July). COMPARATIVE CHARACTERISTICS OF THE MORPHOLOGICAL PARAMETERS OF THE LIVER AT DIFFERENT PERIODS OF TRAUMATIC BRAIN INJURY. // *In Euro-Asia Conferences* (pp. 139-142).
19. Aziza Zokirovna Olimova. Частота Встречаемости Миомы Матки У Женщин В Репродуктивном Возрасте. // *JOURNAL OF ADVANCED RESEARCH AND STABILITY (JARS). Volume: 01 Issue: 06 | 2021. 551-556 p*

20. Aziza Zokirovna Olimova. РЕПРОДУКТИВ ЁШДАГИ ЭРКАКЛАРДА БЕПУШТЛИК САБАБЛАРИ: БУХОРО ТУМАНИ ЭПИДЕМИОЛОГИЯСИ. // SCIENTIFIC PROGRESS. 2021 й 499-502p
21. Aziza Zokirovna Olimova. MACRO- AND MICROSCOPIC STRUCTURE OF THE LIVER OF THREE MONTHLY WHITE RATS. // ACADEMIC RESEARCH IN EDUCATIONAL SCIENCES /2021 й. 309-312 p
22. Aziza Zokirovna Olimova. Cytological screening of cervical diseases: pap test research in the bukhara regional diagnostic center for the period 2015-2019 // Web of Scientist: International Scientific Research 3 (7), 2022, 121-128
23. OA Zokirovna Technique for cutting biopsy and surgical material in the practice of pathological anatomy and forensic medicine // Web of Scientist: International Scientific Research Journal 3 (7), 2022, 116-120