

Morphological Aspects of the Liver of White Outbred Rats After Severe Traumatic Brain Injury Caused Experimentally in the Form of a Road Accident

Olimova Aziza Zokirovna, TeshaeV Shukhrat Jumaevich

Bukhara State Medical Institute

Article Information

Received: December 06, 2022

Accepted: January 07, 2023

Published: February 08, 2023

Keywords: *rat, liver, morphology, traumatic brain injury*

ABSTRACT

The study was conducted on 60 white outbred rats 3 months of age. The fixed animals were accelerated on a vehicle made by hand in the form of a vehicle on wheels, and hit a wooden barrier with the frontal part of the head. As a result of this experiment, 16 white rats died on the spot. All dead rats during the experiment were instantly decapitated by decapitation. After opening the abdominal cavity, the liver was removed. The seized liver was examined and studied, and its dimensions were measured in the prescribed manner. The liver was fixed in Bouin's solution and embedded in paraffin according to generally accepted rules. Next, histological sections were prepared with a thickness of 6-7 μm , which were stained with hematoxylin-eosin. Morphometric studies of the liver tissue were performed under an NLCD-307B microscope. In 3-month-old rats, the total thickness of the liver wall in its various ranges remained unchanged, but some changes in the tissue structures of the liver were revealed.

Relevance. According to the WHO, injuries rank third among the causes of general mortality of the population, and in the group of people under 45 years old - the first place [I.V. Bratishchev, 2002]. Traumatic brain injury (TBI) is the leading cause of mortality in trauma patients [Kalsotra D., 2007].

The high level of mortality and disability in patients with brain damage determines the undoubted social and medical significance of the TBI problem. The frequency and severity of craniocerebral injuries, high mortality (up to 26.8-81.5%) [2,3,4], determine the relevance of this problem and require further development of methods for treating TBI and its complications. The most vulnerable in TBI are the so-called. "shock" organs - lungs, liver, kidneys.

Traumatic brain injury (TBI) is a multifunctional disease characterized by high mortality and disability in a significant part of the victims.

To date, there have been no detailed studies of the effects of traumatic brain injury on the structure of the liver. Currently, at the Department of Pathological Anatomy of the Bukhara State Medical Institute named after Abu Ali ibn Sino, studies are ongoing on the effect of traumatic brain injury on changes in the morphological and functional parameters of the liver, which will deepen the understanding of the mechanisms of an adequate response of the liver to the effects of exogenous factors and the order of possible sequential changes in the morphometric parameters of this organ.

The purpose of the study was to study the morphometric parameters of the liver in 3-month-old white outbred rats with severe traumatic brain injury.

Materials and methods. The study was conducted on 60 white outbred rats 3 months of age. Animals were fixed in a device made by hand in the form of a vehicle on wheels, fixed rats accelerated on the vehicle and hit a wooden barrier with the frontal part of the head. As a result of this experiment, 16 white rats died on the spot. All rats that died during the experiment were decapitated on the spot by instantaneous decapitation. After opening the abdominal cavity, the liver was removed for further study. All conducted experiments on laboratory animals were carried out in accordance with the Declaration of Helsinki of the International Medical Association of 1964, as well as declarations adopted in 1975, 1983, 1989, 1996, 2000, 2002, 2004, 2008, 2013.

Separated liver tissue and its parts were fixed in Bouin's solution and embedded in paraffin. Subsequently, sections of 6-7 μm in size were prepared and stained in hematoxylin-eosin solutions. Morphometric studies were carried out on an NLCD NOVEL-307B microscope (China).

Research results. Acute dyscirculatory and hemorrhagic changes in the liver after a traumatic brain injury indicate rapid death after injury, an increase in metabolic-dystrophic and necrobiotic changes in the center of the lobes corresponds to 24 hours, massive hemorrhages in the center of the lobes, "shock liver" in the form of centrilobular liver necrosis. Morphometric parameters of the hemomicrocirculatory bed and parenchymal structures of the liver in severe traumatic brain injury are shown in Table 1.

The diameter of the central vein was 56.12 ± 1.40 mkm, interlobular vein 89.20 ± 2.40 mkm, interlobular artery 27.12 ± 2.47 mkm, interlobular bile duct 14.10 ± 1.16 mkm. The area of hepatocytes was 493.9 ± 12.20 mkm, nuclei 60.10 ± 2.24 mkm, cytoplasm 432.10 ± 1.08 mkm.

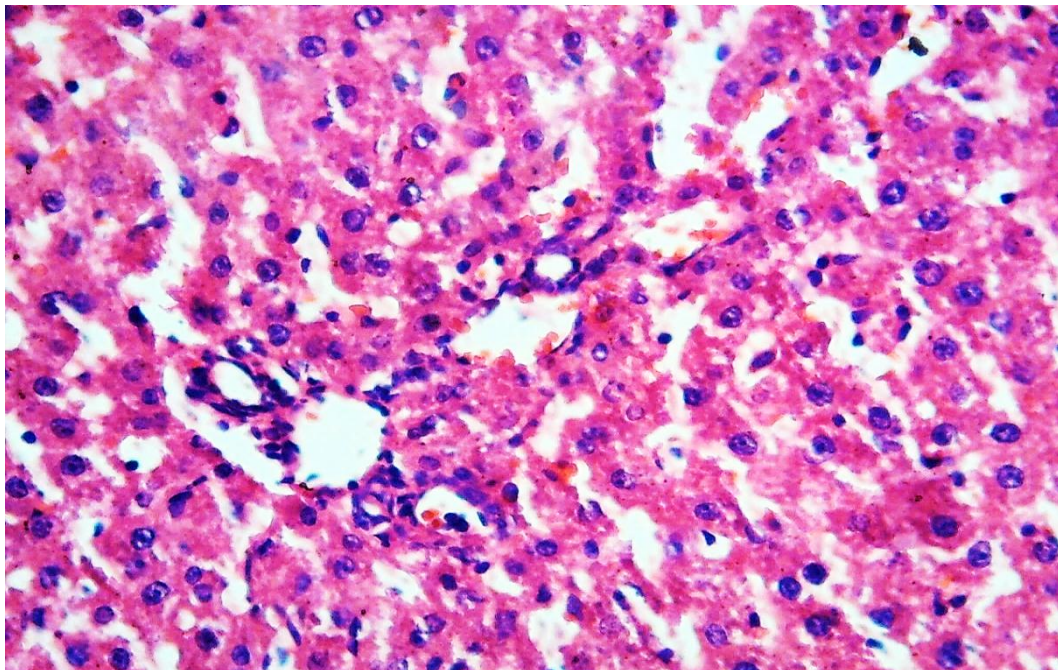


Fig. 1. Morphometric parameters of the liver of white outbred rats on the 1st day after brain injury in the experiment. Expansion of sinusoidal spaces and capillaries, expansion of central venous vessels, focal dystrophic changes in hepatocytes are observed. Hematoxylin-eosin dye. Ok 10x20.

Table 1. Group II - morphometric parameters of the hemomicrocirculatory system and parenchymal structures of the liver of purebred rats on the 1st day after brain injury (n = 60);

№	Morphometric index Diameter, mkm.	Meaning indicator (M±m) Diameter, mkm. In the normal	Morphometric indicator Diameter, mkm. In the experiment	Meaning indicator (M±m) Diameter, mkm. Fine
1	central vein	54,05 ± 0,88	central vein	56,12±1,40
2	interlobular vein	87,82 ± 1,85	interlobular vein	89,20±2,40
3	interlobular artery	25,65 ± 2,43	interlobular artery	27,12±2,47
4	interlobular bile duct	13,88 ± 0,82	interlobular bile duct	14,10±1,16
5	sinusoidal capillary	28,38 ± 0,94	sinusoidal capillary	30,46±1,58
Area, mkm				
1	hepatocytes	487,2 ± 11,16	hepatocytes	493,9±12,20
2	nuclei	58,91 ± 1,88	nuclei	60,10±2,24
3	cytoplasm	428,02 ± 9,20	cytoplasm	432,10±1,08
Nuclear-cytoplasmic ratio		0,137 ± 0,06		

Conclusions. The conducted studies allow us to conclude that in severe cases of traumatic brain injury - acute dyscirculatory and hemorrhagic changes in the liver prevail on the 1st day after TBI in the experiment; changes develop in the form of a "shock liver" expansion and plethora of the central veins and sinusoids, and then an increase in the permeability of their walls, venous plethora and diapedetic hemorrhage. Morphometric indicators of the hemomicrocirculatory system and parenchymal structures of the liver of outbred rats on the 1st day after brain injury, there is an expansion of sinusoidal spaces and capillaries, an expansion of the central venous vessels, focal dystrophic changes in hepatocytes and an increase in the area of hepatocytes compared to normal values.

Literature:

1. Калинина Н. М. Травма: воспаление и иммунитет / Н. М. Калинина, А. Е. Сосюкин, Д. А. Вологжанин // Цитокины и воспаление. 2005. Т.4, № 1. - С.28-35.
2. Кондаков Е.Н., Кривецкий В.В. Черепно-мозговая травма: рук-во для врачей неспециализированных стационаров. - СПб.: СпецЛит, 2002. - 271 с.
3. Коновалов А. Н., Лихтерман Л. Б., Потапов А. А. Клиническое руководство по черепно-мозговой травме. - М.: Антидор, 2002. - Т.1. - 550 с.
4. Мартынова ОВ, Анциферов ОВ, Мартынов МА, и др. Исследование нейродинамических нарушений у крыс при черепно-мозговой травме. Научные результаты биомедицинских исследований. 2019;5(3):50-63.
5. Рыбакина Е.Г., Шанин С.Н., Фомичева Е.Е., Филатенкова Т.А., Дмитриенко Е.В. Клеточно-молекулярные механизмы изменения защитных функций организма при черепно-мозговой травме и попытка лечения // Медицинский академический журнал, 2014. Т. 14, №4. С. 55-62.
6. Судебно-медицинская экспертиза черепно-мозговой травмы. Справочно-информационные материалы. К у р с к. 2014

7. И.В. Фурсов, В.В. Могила «Внечерепные осложнения тяжелой черепно – мозговой травмы» Та в р и ч е с к и й м е д и к о - б и о л о г и ч е с к и й в е с т н и к . 2013. том 16. №3. ч.3 (63) С.146-149
8. Лебедева Елена Ивановна Сравнительная морфофункциональная характеристика печени белой крысы и человека в норме и при токсическом поражении // Автореферат диссертации на соискание ученой степени кандидата биологических наук. Минск 2016
9. Aziza Zokirovna Olimova, (2021, July). COMPARATIVE CHARACTERISTICS OF THE MORPHOLOGICAL PARAMETERS OF THE LIVER AT DIFFERENT PERIODS OF TRAUMATIC BRAIN INJURY. // In Euro-Asia Conferences (pp. 139-142).
10. Aziza Zokirovna Olimova. MACRO- AND MICROSCOPIC STRUCTURE OF THE LIVER OF THREE MONTHLY WHITE RATS. // ACADEMIC RESEARCH IN EDUCATIONAL SCIENCES /2021 й. 309-312 p
11. OA Zokirovna Technique for cutting biopsy and surgical material in the practice of pathological anatomy and forensic medicine // Web of Scientist: International Scientific Research Journal 3 (7), 2022, 116-120
12. Aziza Zokirovna Olimova, (2021, July). COMPARATIVE CHARACTERISTICS OF THE MORPHOLOGICAL PARAMETERS OF THE LIVER AT DIFFERENT PERIODS OF TRAUMATIC BRAIN INJURY. In Euro-Asia Conferences (pp. 139-142).
13. Aziza Zokirovna Olimova. Частота Встречаемости Миомы Матки У Женщин В Репродуктивном Возрасте. JOURNAL OF ADVANCED RESEARCH AND STABILITY (JARS). Volume: 01 Issue: 06 | 2021. 551-556 p
14. Aziza Zokirovna Olimova, Sanoyev Bakhtiyor Abdurasulovich. OVARIAN DISEASES IN AGE OF REPRODUCTIVE WOMEN: DERMOID CYST. Volume: 01 Issue: 06 | 2021. 154-161 p
15. Aziza Zokirovna Olimova. РЕПРОДУКТИВ ЁШДАГИ ЭРКАКЛАРДА БЕПУШТЛИК САБАБЛАРИ: БУХОРО ТУМАНИ ЭПИДЕМИОЛОГИЯСИ. SCIENTIFIC PROGRESS. 2021 й 499-502p
16. Aziza Zokirovna Olimova. MACRO- AND MICROSCOPIC STRUCTURE OF THE LIVER OF THREE MONTHLY WHITE RATS. ACADEMIC RESEARCH IN EDUCATIONAL SCIENCES /2021 й. 309-312 p
17. Sanoyev Bakhtiyor Abdurasulovich, Olimova Aziza Zokirovna. Pathology of Precancerous Conditions of the Ovaries in Women of Reproductive Age. Volume: 01 Issue: 06 | 2021.
18. Aziza Zokirovna Olimova. Cytological screening of cervical diseases: pap test research in the bukhara regional diagnostic center for the period 2015-2019 // Web of Scientist: International Scientific Research 3 (7), 2022, 121-128