

### Results of Treatment of Patients with Obstructive Jaundice

U. O. Abidov

Bukhara branch of the Republican Scientific Center of Emergency Medical Care, Bukhara State Medical Institute

#### Article Information

**Received:** March 25, 2023

**Accepted:** April 26, 2023

**Published:** May 27, 2023

**Keywords:** *mechanical jaundice, minimally invasive interventions, biliary decompression.*

#### ABSTRACT

A retrospective analysis of the clinical data of 2970 patients with mechanical jaundice of benign and malignant etiology was carried out. Mechanical jaundice of benign origin was observed in 2251 (75.8%), malignant - in 719 (24.2%) patients. All patients admitted with cholestasis syndrome underwent standard general clinical and biochemical tests. Verification of the diagnosis of mechanical jaundice was performed using ultrasound, FGDS, MRCPG, ERCP. More than 90% of patients underwent minimally invasive surgical interventions, which allowed to improve the results of treatment.

One of the main and intractable problems of surgery, until today, is the diagnosis and treatment of mechanical jaundice syndrome (MJ). In recent years, there has been a tendency to increase the number of patients with mechanical jaundice, which remains an important medical and social problem all over the world [12,21,23,25,26].

Correct and timely diagnosis of its cause is of great importance, determining the further tactics of the patient's management and the results of his treatment.

Being that MJ is not an independent nosological form, there are no uniform statistical data, as well as gender-age characteristics [20]. In patients of surgical hospitals with MJ, the proportion of tumor causes is 25.5 -59 %, non-tumor-11.6-74.4 % [2.7].

The reasons for this are the steady growth of patients with this pathology, an increase in the number of elderly and senile people, children and pregnant women among them. According to E. I. Galperin et al. [21] up to 10% of the world's population suffer from this pathology, while the incidence rate increases by about 2 times every 10 years.

According to scientific forecasting, the incidence of biliary system organs will grow by 30-50% in the next 15 years in the world, which is explained by the lifestyle and the nature of nutrition, hereditary factors [3,4,5]. There is a general process of "rejuvenation" of the contingent of patients with sub-hepatic cholestasis. To date, there is an increase in the mortality rate for mechanical jaundice among people of working age [18].

More than 90% of patients are admitted as an emergency at the late stages of the disease. Over the past 10 years, there have been changes in the structure of the causes of mechanical jaundice: the proportion of tumor diseases has increased [8].

The goal of numerous studies both here and abroad is to reduce the high postoperative mortality in this syndrome [6,8,24,25,26]. Despite the success in the surgical treatment of breast cancer achieved through the introduction of modern radiation and endoscopic techniques into clinical practice, the issues related to the timing and types of decompression interventions, as well as methods of prevention and treatment of postoperative liver failure remain relevant [6-9].

More than 80% of patients with malignant tumors of the pancreatobiliary region, complicated by mechanical jaundice and cholangitis, cannot undergo radical surgery [8,14]. These patients need help with guaranteed low mortality, low complication rate and short hospitalization [27]. Retrograde nasobiliary and antegrade drainage of the common bile duct (choledocha) are the most common variants of bile drainage in patients with bile hypertension [15,16].

Retrograde stenting of the bile ducts can be an independent method of treatment for benign strictures caused by pathology of the pancreas and bile ducts, as well as a component of multi-stage treatment in the preoperative period in patients with cholelithiasis [28].

One of the methods of improving the results of treatment of MJ is preliminary biliary decompression, which allows to prepare the patient for radical surgery with minimal trauma, avoiding general anesthesia, which is especially true for elderly and senile patients [10,27]. Currently, a two-stage tactic is used in the treatment of MJ, this is endoscopic papillosphincterotomy for GI with subsequent cholecystectomy, stenting for hepato billiar pancreato duodenal zone tumors and after radical surgery [7,10,19,24,25,26].

## **MATERIALS AND METHODS.**

The work is based on the analysis of the results of treatment of 2970 patients with mechanical jaundice (MJ). There were 1,351 men (46.2%) and 1,619 women (53.8%).

The age of patients ranged from 18 to 90 years, and more than 60% were elderly and senile patients, burdened with concomitant pathology and a high degree of operational risk. The causes of mechanical jaundice in 75.8% (n=2251) of patients were benign diseases, in 24.2% (n=719) - malignant (Table.1). An increase in the frequency of malignant neoplasms of the hepatopancreatoduodenal zone from 2010 to 2020 was noted (Fig.1.) Among malignant neoplasms, an increase in the pancreatic tumor in dynamics is characteristic (Fig. 2.)

During the period 2010 to 2020, the Bukhara Branch of the Republic centre of emergency aid produced 2964 ERPCHG and 2747 Endoscopic papillosphincterotomy (EPST). According to the results of endoscopic retro-pancreatic cholangiography (ERPCHG), the causes of mechanical jaundice were: choledocholithiasis - in 1977 (including residual choledocholithiasis), a tumor of the large duodenal papilla (LDP) - in 129 patients, a tumor of the pancreatic head 365 and strictures of the terminal choledochus - 76 patients; tumors of the liver gate, liver metastases from other tumor localities and narrowing of the common bile duct(CBD) due to pericholedocheal lymphadenopathy-138 patients, a ruptured echinococcal cyst of the liver into the common bile duct-126 patients, hepaticofasciola in 3 patients, Mirizzi syndrome (SM) - in 15; choledoch cyst-3. (Table 1.)

EPST was performed in 2747 (97%) patients. Lithoextraction of stones from the CBD was performed in 1842 (93.2%) patients. If it was impossible to remove stones from the CBD due to the large size of the concretions, mechanical lithotripsy was performed. This operation was successfully performed in 91 patients (4.6%).

Failures of mechanical lithotripsy were in 44 (2.2%) patients associated primarily with parapapillary diverticula and dense stones.

For various reasons, ERPHG (inability to access LDP, previously performed gastric resections according to Billroth II, parapapillary diverticula, etc.) could not be performed in 42 patients

(Table 2).

The patency of the bile duct was eliminated by an open (traditional, with bilirubin values below 100 mmol.l) or antegrade by through cutaneous through hepatic cholangistomy (interventional radiological way).

If retrograde decompression of the biliary tract was impossible, through cutaneous through hepatic cholangiography and through cutaneous through hepatic cholangistomy were used in 44 patients.

The duration of mechanical jaundice was from 2 to 30 days. Among all patients under the age of 55, the most common cause of mechanical jaundice was choledocholithiasis (63%), while after 55 years - malignant tumors of the hepaopancreatoduodenal zone (65%).

Complications associated with mechanical jaundice were detected in 35 (39.3%) patients upon admission.

Fig. 1.

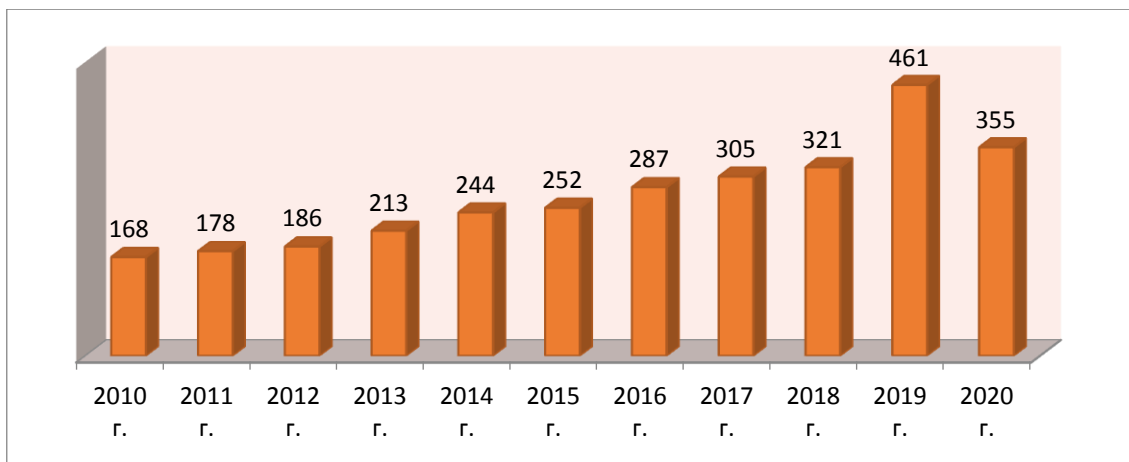


Fig. 1. The number of patients with mechanical jaundice n=2970

Acute cholangitis as a complication of mechanical jaundice was diagnosed in 220 (7.4%) patients, before and after the decompression period.

Fig. 2.

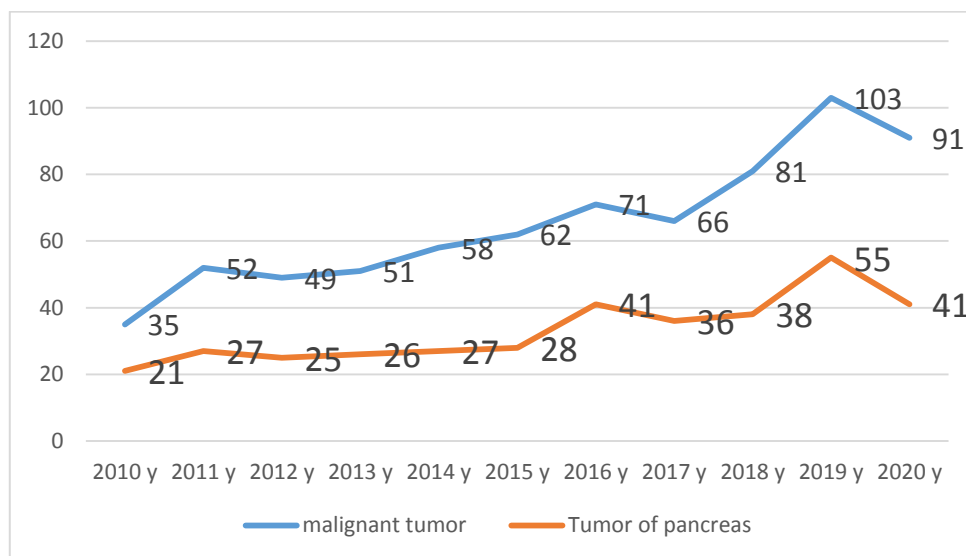


Fig. 2. Number of patients with mechanical jaundice of malignant origin (n=2970)

Of the 220 patients with purulent cholangitis, 87(39.5%) underwent nasobiliary drainage and sanitation of the gallbladder with solutions of decosan and 20 ml (5 ml.liter) with a solution of azonated sodium chloride. Scientific work is being conducted on the effect of ozonated solution on the course of acute cholangitis.

Fig. 3.

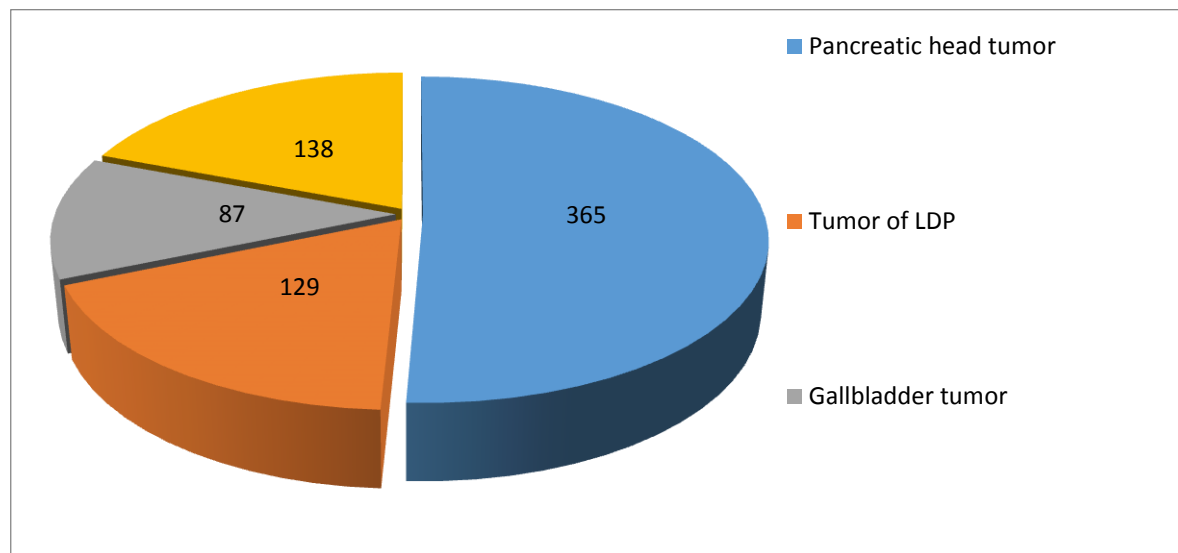


Fig. 3. The proportion of patients with mechanical jaundice of malignant origin

## RESULTS AND DISCUSSIONS.

For MJ caused by choledocholithiasis, minimally invasive interventions were used, the first stage was performed by ERPHG and endoscopic papillo-sphincterotomy (EPST) followed by lithoextraction. Out of 1977 patients with choledocholithiasis, lithoextraction was performed in 1842 (93.2%) patients. With large sizes of concretions, mechanical lithotripsy was performed in 91 patients (4.6%). Failures of mechanical lithotripsy were in 44 (2.2%) patients associated primarily with parapapillary diverticula and dense stones. After normalization of the indicators of the functional state of the liver, the second stage of laparoscopic or open cholecystectomy was performed. The choice of the operation method depended on the destructive changes in the gallbladder wall, peritonitis and the presence of cholangitis.

Table 3. Stage II after decompressive interventions in patients with choledocholithiasis in patients with mechanical jaundice

Nº	Types of operations	quantity
1.	Laparoscopic cholecystectomy (after ERPHG and lithoextraction).	1150 (58%)
2.	Traditional cholecystectomy (after ERPHG and lithoextraction).	717 (36,3%)
3.	Traditional cholecystectomy with drainage of the choledochus according to Pikovsky.	25 (1,3%)
4.	Traditional cholecystectomy, choledochotomy, drainage of the choledochus by Ker.	60 (3%)
5.	Traditional cholecystectomy with drainage of the choledochus according to Vishnevsky.	25(1,3%)
	Total	1977

In case of suspected duodenal papilla stenosis, 76 (2.6%) patients underwent endoscopic retrograde cholangiopancreatography, followed by pappylosphincterotomy. Therapeutic EPST is performed in all cases with benign diseases of the LDP to restore the patency of the ducts. The

breakthrough of echinococcal cysts into the bile ducts also caused mechanical jaundice in 126 patients. It was performed by removing the chitin shell (followed by surgical treatment).

**Tumors of the hepatopancreatoduodenal zone.** More than 80% of patients with malignant tumors of the hepatopancreatobiliary region, complicated by mechanical jaundice and cholangitis, cannot be subjected to radical surgery. These patients need help with guaranteed low mortality and low frequency of complications [8,14,27].

With a proximal location of the tumor in the hepatic ducts, pronounced biliary hypertension, percutaneous transhepatic drainage is used. With a distal location of the tumor, these tasks are solved using endoscopic techniques. This tactic makes it possible to achieve effective decompression of the biliary tract with low rates of postoperative complications and mortality.

In our branch, the method most often used was retrograde decompression of the intrahepatic bile ducts, plastic stents of various sizes (F8 -12, 15 cm) were used and it was possible to decompress, even with proximal tumors. At the same time, performing this manipulation in pancreatobiliary tumors was often impossible due to the localization of the narrowing (proximal location), its extent and the density of the tumor tissue. In these cases, the percutaneous transhepatic decompression technique under X-ray television or ultrasound control was preferred. Out of 719 patients with malignant diseases of the hepatopancreatobiliary zone, due to the inability to install stents retrograde, 44 (6.1%) patients were installed with CHCs.

From instrumental ultrasound, magnitoresonance cholangiography, ERPChG together with the cancer marker CA-19-9, it makes it possible to assess the prevalence of the process and the success of surgical treatment.

Transpapillary endoprosthetics of hepaticocholedocha are performed mainly for tumors of the pancreatobiliary zone and strictures. During the study period, 189 plastic stands were installed. We use standard plastic endoprostheses from Olympus (Japan) and Willson-Cook (USA). The terms of functioning of such endoprostheses are 4-5 months.

Complications sometimes occur during and after ERPHG and EPST. From the analysis of our data, ERPHG and EPST were accompanied by a number of complications. Among the complications, there were 22 (0.7%) bleeding after EPST, stopped conservatively, 3 insertion of the Dormia basket probe during lithoextraction, which required surgical treatment. In 18 patients (0.6%), post-contrast pancreatitis was noted, which required surgical treatment in 2 patients, 16 patients were cured by the conservative method. Effective measures for the prevention of complications are adequate, effective premedication and gentle technique of execution. The most serious complication is duodenal perforation with the development of retroperitoneal phlegmon and the fatal outcome was in 1 case (0.03%).

Thus, summarizing all the above, it can be stated that over the past 10 years there have been tangible positive changes in the quality of providing qualified care to patients with such severe conditions as MH and its complications.

### **Conclusions:**

1. Minimally invasive endoscopic and percutaneous trans hepatic decompression interventions are an effective way to restore bile flow in case of biliary system obstruction. These methods make it possible to quickly and effectively eliminate MJ and cholangitis, and make it possible to perform surgical interventions in the most favorable conditions.
2. At the 1st stage of treatment in patients with mechanical jaundice, it is advisable to perform temporary decompression of the bile ducts as a preparation for the main (2) stage of treatment, and in other inoperable cases - as a complete replacement for surgical treatment.

**List of used literature:**

1. Bykov A.D., Dorogan D. A. Comparative effectiveness of methods of drainage of extrahepatic bile ducts in mechanical jaundice // Vestn. Buryat State University. - 2009. - No. 12. - pp. 152-154.
2. Vetshev P. S. Mechanical jaundice: causes and diagnostic approaches (lecture) // Annals of surgical hepatology. - 2011. - Vol. 16, No. 3. - p. 50-57.
3. Vetshev, P. S. Minimally invasive percutaneous technologies: history, traditions, negative trends and prospects // P. S. Vetshev, G. H. Musaev, S. V. Bruslik // Annals of surgical hepatology. - 2014. - No. 1. - p. 12-16.
4. Grigorieva I. N. Polymorphism of the AOE gene and lithogenicity of bile in persons with hereditary burden of GI // I. N. Grigorieva, M. A. Slobodchikova, V. N. Maksimov // Materials of the 10th Congress of NOGR. - M., 2010. - pp. 81-82.
5. Deikalo I. M. Algorithm of diagnostics and minimally invasive treatment of mechanical jaundice // Hepatology and gastroenterology. - No. 1. - 2018 "I. Y. Gorbachevsky Ternopil State Medical University".- Ternopil, Ukraine.- Pp. 75-79.
6. Eliseev S. M., Kornilov N. G., Chikoteev S. P., Gumerov R. R. Justification of surgical tactics in mechanical jaundice (Analytical review) // Bulletin of the VSSC SB RAMS. - 2010, - № (75) - Pp. 233-237.
7. Zharikov Yu. O., Shevchenko T. V., Zhao A.V. Biliary decompression in tumors of the proximal bile ducts // Vishnevsky Institute of Surgery of the Ministry of Health of the Russian Federation. - Clinical medicine. - № 9. - 2015. Pages 11-15.
8. Zakharova A.V. Improvement of diagnostic and surgical tactics in patients with mechanical jaundice // Prkaticeskaya meditsina.- 2013. - p. 156-159.
9. Zemlyanoi V. P., Nepomnyashchaya S. L., Rybkin A. K. Biliary decompression in case of mechanical jaundice of tumor genesis // Practical oncology. - 2004. - Vol. 5. - No. 2. - pp. 85-93.
10. Kasatkin V. F., Kit O. I., Trifonov D. S. Experience of percutaneous bile-removing interventions in patients with mechanical jaundice of tumor etiology // Siberian Oncological Journal. - 2008. - № 4 (28). - Pp. 51-54.
11. Korobka V. L., S. V. Tolstopyatov, Dabliz R. O., Shapovalov A.M. Biliary decompression in patients with mechanical jaundice // "Rostov Regional Clinical Hospital", Rostov-on-Don. - - Innovative medicine of Kuban.- No. 4. - 2019. pp. 24-31
12. Kotovsky A. E., Glebov K. G. Endoscopic transpapillary stenting of the bile ducts // Ann. khir. hepatol. - 2008. - Vol. 13, No. 1. - pp. 66-71.
13. Kulezneva Yu. V., Izrailov P. E., Kapustin V. I. Percutaneous decompression of the bile ducts in mechanical jaundice of tumor genesis // Moskov. hir. zh. - 2010. - No. 2. - pp. 45-51.
14. Malyarchuk V. I., Bazilevich F. V., Abashidze Z. Sh., etc. Preoperative drainage in the treatment of patients with tumor obturation of the biliary tract //Ann. hir. hepatol. - 2008. - Vol. 8, No. 2. - p. 170.
15. Maslov I. S. Ways to improve the treatment of patients with mechanical jaundice //Maslov I. S., Shaimardanov R. S., Korobkov V. N., Khisameev I. G. Practical medicine. - - 2014. 78-81 p.



16. Natal'sky A. A. Modern principles of diagnosis and treatment of mechanical jaundice syndrome: autoref. diss. dr. Science. A. A. Natal'sky. - R., 2015. - 36.
17. Patyutko Yu. I., Kotelnikov A. G., Dolgushin B. I. Methods of bile removal in case of mechanical jaundice of tumor nature // *Vestn. RONC named after N. N. Blokhin RAMS.* - 2002. - Vol. 13. - No. 1. - pp. 34-39.
18. Pyankova O. B., Busyrev Yu. B., Karpunina T. I. Clinical and epidemiological characteristics of patients with mechanical jaundice syndrome of benign genesis // *Medical almanac.* - 2009. - No. 2. - pp. 173-176.
19. Sokolov S. V., Bayazitova G. R., Salimgareev I. Z., Loginov M. O., Musharapov D. R. Endobiliary surgery in the complex treatment of mechanical jaundice // *Medical Bulletin of Bashkortostan. Tom. - 1. - № 3 (75).* - 2018. Mtr. 23-27.
20. Tarasenko S. V., Natal'sky A. A., Levitin A.V. The choice of the method of surgical decompression in extrahepatic cholestasis // *Russian Medico-biological Bulletin. Academician I. P. Pavlov.* - 2008. - No. 3. - pp. 118-123.
21. Fedorov, V. E. Mechanical jaundice of non-tumor genesis: monograph /V. E. Fedorov, A. P. Vlasov, I. V. Fedoseikin. - M.: Nauka, 2014. -233 p.
22. Khadjibaev A.M. Complex video endoscopic, radiation diagnostics and minimally invasive treatment of mechanical jaundice syndrome // *Khadjibaev F. A., Tilemisov S. O. Endoscopic surgery.* 2015;21(1):7-12.
23. Khadjibaev F. A. Minimally invasive X-ray endobiliary interventions in mechanical jaundice of tumor genesis // *Khadjibaev F. A., Tilemisov S. O., Khashimov M. A., Bulletin of Emergency Medicine,* 2014, No. 3 p. - 36-38.
24. Khadzhibaev F. A. The role and place of endobiliary interventions in the surgical treatment of mechanical jaundice of benign genesis. F. A. Khadzhibaeva: Abstract of the abstract of the dissertation of the doctor. sciences. 2015. - 88 p.
25. Khrustaleva M. V. Modern endoscopic transpapillary methods of treatment of mechanical jaundice // *Annals of the National Research Center of the Russian Academy of Medical Sciences,* 1997. - pp. 39-42.
26. Shapovalyants S. G., Pankov A. G., Mylnikov A. G., etc. Possibilities of endoscopic bilioduodenal prosthetics in the treatment of tumor and scar strictures of extrahepatic bile ducts // *RZHGGK.* - 2008. - Vol. 18, No. 6. - pp. 57-63
27. Suda K., Otsuka M., Ambaru S., Kimura F. et al. Risk factors for impaired liver function after extended liver resection in malignant neoplasms of the biliary tract // *Am. J. surg.* - 2009. - Volume 197 (6). - pp. 752-758.
28. Van der Haag N. A., Raus E. A., van Eyck K. H., Bruno M. J. et al. Preoperative drainage of the biliary tract in pancreatic head cancer // *N. Engl. J. Med.* - 2010. - Vol. 362, N 2. - pp. 129-137.